

Biochemical Changes of Liver That Infected with *Entamoeba Histolytica* in White Rats

Ahmed Khudhair Obayes Al-Hamairy^{*1}, Halla Abdul-Hadi Abdul-Ghani Chabuk¹, Haidar Kamil Zaidan Al-Saadi²

Abstract- This study was carried out in the animal house of the Science College, Babylon University for the period from October 2012 till February 2013. This study included, 20 white Swiss males *Rattus rattus* ages between 3-4 months, and weights between 250-300 gm. Animals were divided into five groups (2, 4, 8, 12) weeks and the fifth group considered as control group each group included (four males). Four groups were infected with suspension *E. histolytica* that bring from stools patients attending to the Al-Hilla Hospital laboratory, every rat gives about 10^3 cysts per milliliter of *E. histolytica* through oral administration. And the fifth group treated orally with distilled water. The rats liver were studied functionally by measuring the level of enzymes GOT, GPT, ALP. The tests of liver enzymes, showed that the level of the enzyme GOT, GPT, ALP having significant increased ($P < 0.05$) in the male rats treated *E. histolytica* suspension compared to control group. The infection with *E. histolytica* established histological changes in the organs especially the liver as apoptosis death of cells as well as changes in biochemical parameters (ALP, GOT, GPT).

Index Terms- Entamoeba histolytica, Biochemical changes, Apoptosis.

1 INTRODUCTION

Amoebiasis caused by *Entamoeba histolytica* and is the second cause of global morbidity and mortality due to parasitic diseases in humans, It causes more than 100,000 deaths each year and is responsible for 50 million cases of diarrhea each year (15, 26). Infected persons display a wide range of disease severity, reflecting the contribution of the patient's immune and nutritional status (11). *E. histolytica* inhabits the large intestine, It is acquired when infective cysts are ingested through contaminated food or water. Excystation releases trophozoites into the terminal ileum and from there parasites migrate to the colon where they colonize (19). Some parasites undergo encystment in the descending colon, resulting in passage of mature infective cysts in the stool and perpetuation of the life cycle through fecal-oral spread. In 90% of cases amoebic infections are asymptomatic and self-limiting (14). But approximately in 1% of the cases, trophozoites penetrate the intestinal mucosa and spread to other organs, producing extra-intestinal amoebiasis, among which amoebic liver abscess (ALA) is the most common (4). *E. histolytica*

***Corresponding Author:** Tel: 009647810430761,
Email: alhamiary2009@yahoo.com

induces apoptosis, both, in human cells, and during the development of ALA in hamsters and mice (5). It has also been found that the death of hepatocytes and immune cells during amoebic invasion is not only due to the cytolysis activity of the trophozoites, but also because of an apoptotic process (20). Abscesses located just below the diaphragm can lead to pleural pain or referred right shoulder pain. Liver alkaline phosphatase levels (ALP) and alanine aminotransferase levels (GOT, GPT) are elevated in acute liver abscess, which may, however, reverse over time. Males are ten times more likely to present with liver abscess than females and middle-age and young adults more than children (11). Aminotransferase levels are sensitive indicators of liver-cell injury and are helpful in recognizing hepatocellular diseases such as liver abscess, levels of this enzyme are accordingly more specific indicators of liver injury. Both enzymes are released into the blood in increasing amounts when the liver cell membrane is damaged. Necrosis of liver cells is required for the release of the aminotransferases (10). The aim of this study to determine the level of liver enzymes (alkaline phosphatase levels (ALP) and alanine aminotransferase levels (AST, ALT) and its relationship with *E. histolytica* infection in rats.

¹ Biology dept. College of science for women, Babylon University, Hilla, Babylon, Iraq

² Biology dept. College of science, Babylon University, Hilla, Babylon, Iraq

2 MATERIALS & METHODS

Isolates of *E. histolytica* from some patients in Babylon Hospital in Hilla city, sample collection from the period lies between October 2012 till February 2013, stool patients selected for this study were usually suffering from diarrhea, vomiting, dysentery, abdominal pain and stools were contain blood, mucus. Then keep in sterile plastic container and this stool samples were examined in advanced parasitology lab. of Science College for women by direct smear methods. A drop of Lugol's iodine was added and mixed with small piece of feces and examined under compound microscope to diagnosed the cysts and trophozoite of *E. histolytica*, added to this stool normal saline proportion 1:1 and take one milliliter of suspension that contain about 10^3 cysts were infected of 20 males rats (divided into five groups 2 weeks, 4 weeks, 8 weeks, 12 weeks and the fifth group consider as control group each group included (four males) orally administration, their weight range between 250 - 300 gm. Then anesthesia animals using chloroform dose and open the abdominal cavity until the sternum using scissors medical and draw blood directly from the heart in a way (Heart puncture) using a syringe medical sterile capacity of 5 ml and put the blood in the jell tube free of material proof coagulation containing material gelatinous help to increase serum formed after centrifugation, left the samples for 30 minutes at room temperature and then put inside the centrifuge centrifuge at 3000 rpm / 10 minutes for the purpose of separation of serum, were taken serum to measure the level of liver enzymes GOT, GPT, ALP (7). Estimated numbers of apoptosis cells in liver tissue infected with Amoebic dysentery, according to the following equation depending on what are say's (8).

Number of dead cells

$$\text{Percentage} = \frac{\text{Number of dead cells}}{\text{Number of living cells}} \times 100$$

3 RESULTS

Result reveals a significant differences ($p < 0.05$) in liver enzymes (GOT, GPT, ALP) comparison with control group. The GOT enzyme tests increased in all infected animals (all groups) when comparison with control group. in spite of the first group (2 weeks), non significant differences ($p > 0.05$) when comparison with second group (4 weeks) and third group (8 weeks) as well as fourth group (12 weeks). But the first and second groups when comparison with third and fourth groups reveals significant differences ($p < 0.05$) as shown in Table (1). The result of GPT enzyme showed increased significantly in the second, third, fourth groups when

comparison with first group. as well as comparison with fourth groups with others. The ALP enzyme reveals high significant differences in the second, third, fourth when comparison with control and first groups, in spite of the differences not reach to significantly among all groups as well as the first group not significant when compared with control group.

Table (1): Effect infected males rats with *E. histolytica* according to different time periods on mean levels liver enzymes GOT, GPT, ALP (I.U/L). Mean \pm SE different index on significant character ($p < 0.05$), Number animals in all group, n = 4

| ENZYMES / GROUPS | MEAN (AST) GOT (I.U/L) \pm SE | MEAN (GPT) ALT (I.U/L) \pm SE | MEAN ALP (I.U/L) \pm SE |
|-------------------|---------------------------------|---------------------------------|---------------------------------|
| Control | ^a 58.48 \pm 2.88 | ^a 60.15 \pm 3.13 | ^a 440.50 \pm 15.87 |
| Group 1 (2 weeks) | ^b 69.33 \pm 3.29 | ^a 57.45 \pm 2.82 | ^a 448.25 \pm 19.18 |
| Group 2 (4 weeks) | ^b 77.00 \pm 2.42 | ^b 74.10 \pm 3.73 | ^b 538.25 \pm 20.45 |
| Group 3 (8 weeks) | ^c 91.50 \pm 4.92 | ^c 90.05 \pm 4.50 | ^b 550.0 \pm 18.17 |
| Group 4 (12 week) | ^c 98.25 \pm 3.94 | ^d 104.00 \pm 4.02 | ^b 566.50 \pm 19.75 |

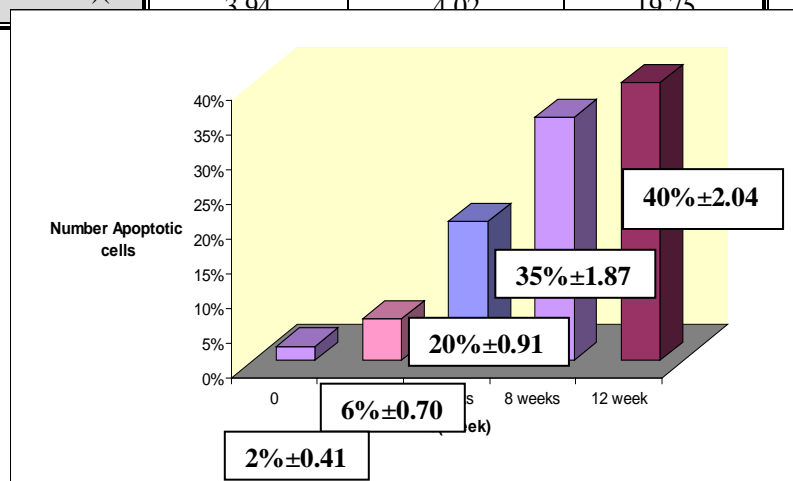


Fig1: Relationship between different time periods (weeks) and mean numbers apoptotic cells after infected with *E. histolytica*.

Were observed in histogram Fig (1) reveals apoptotic index in rats cells infected with *E. histolytica*. The number of apoptotic cells increased directly proportional to the time of infection. Apoptotic cells were recognized to exhibit morphological characteristics, such as nuclear pyknosis and chromatin fragmentation, with cytoplasmic extrusion.

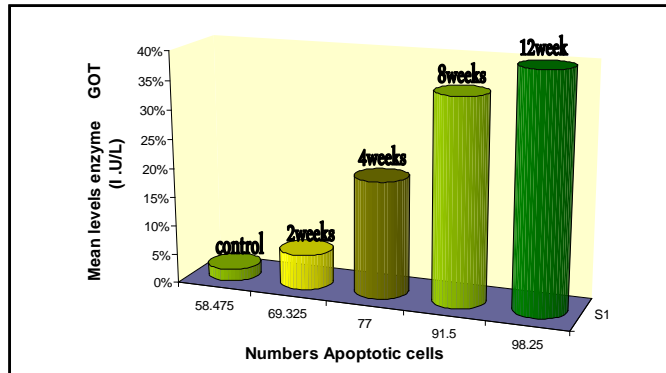


Fig. (2): Relationship between number apoptotic cells and mean levels enzyme GOT (I.U/L) after infected with *E. histolytica*.

Were observed in histogram Fig (2) existence positive relationship between number apoptotic cells & mean levels enzyme GOT (I.U/L) , The greater the levels enzyme GOT increased numbers damaged cells the process of apoptosis .

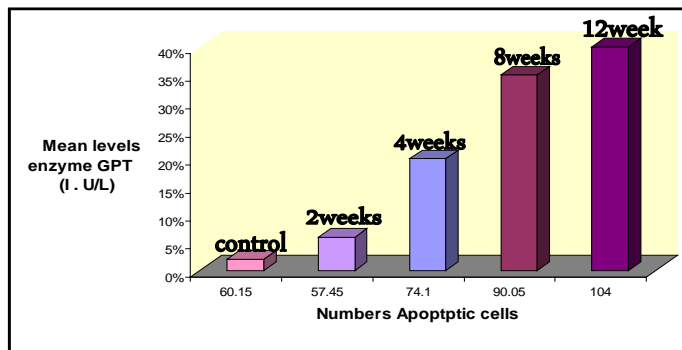


Fig. (3) : Relationship between number apoptotic cells and mean levels enzyme GPT (I.U/L) after infected with *E. histolytica*.

Were observed in histogram Fig (3) existence positive relationship between number Apoptotic cells & mean levels enzyme GPT (I.U/L) , The greater the levels enzyme GPT increased numbers damaged cells the process of Apoptosis .

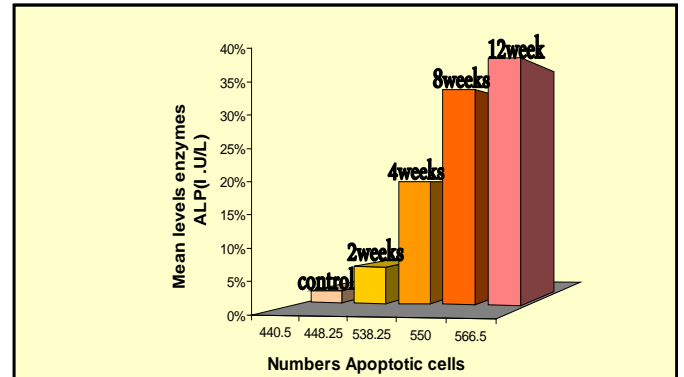


Fig.(4) : Relationship between number Apoptotic cells and mean levels enzyme ALP (I.U/L) after infected with *E. histolytica*.

Were observed in histogram Fig (4) existence positive relationship between number apoptotic cells and mean levels enzyme ALP (I.U/L) , The greater the levels enzyme ALP increased numbers damaged cells the process of apoptosis .

4 DISCUSSION

Amebiasis is a cosmopolitan disease of high prevalence in Africa, Middle east Asia , India , South America and Mexico. Although these countries have improved their living conditions and level of sanitation, the disease is still a major public health problem (9). Following exposure *E. histolytica* inhabits the large intestine, where it causes intestinal amebiasis. However, in approximately 1% of cases, trophozoites disrupt the intestinal mucosa and spread to other organs, causing various forms of extraintestinal amebiasis, of these, amebic liver

abscess (ALA) is the most common (23). The pathogenesis of ALA is very complex and involves host, and parasite factors, as well as micro-environmental conditions (8). The ability of amoebae to destroy host tissue and survive in the liver is accompanied by a strong adaptive response and regulation of proteins, such as amebic virulence factors (6). The most studied virulence factors of *E. histolytica* are the adhesion molecule Gal/Gal NAC lectin (13) , cysteine proteinases (6) , amoeba pore protein (17), and lipophosphoglycan molecules (18). Because of its important role in the pathogenesis of ALA in humans and in animals.

cysteine proteinases from *E. histolytica* have the property to degrade collagen, fibrinogen, elastin and laminin, extracellular matrix elements that trophozoites have to break through in order to cause invasive disease (8).

These proteins are involved in the disruption of cellular monolayers (16). Its inhibition with antisense codons decreases amebic phagocytosis, inflammation of the intestine, and the formation of ALA. It has also been proposed that cysteine proteinases (CP) contribute to create the anaerobic environment that trophozoites require to grow *In vivo* during ALA development (21). Amoebapore proteins from *E. histolytica* are also involved in the

formation of ALA (27). They cause lysis of bacteria and eukaryotic cells (17). Its cytolytic capacity and participation in apoptosis and necrosis induction has been demonstrated *In vivo* (3). According to (24), amoebic liver abscess formation after intraportal inoculation of virulent trophozoites of *E. histolytica* in hamster involves three consecutive phases

(25) who showed that diffusion of amoebic molecules occurs to the endothelium, and hepatocytes located further away die by necrosis. These authors suggest that cytotoxicity can occur due to the secretion of amoebic molecules that can cause toxic effects at a distance, even when there is not close contact between the trophozoites and hepatocytes. were observed in this study apoptotic cells, whose number was increasing with the time of incubation, were presence of pyknotic nuclei, and/or nuclear fragmentation, which are important characteristics of apoptotic cell death were seen .

Indicated a gradual increase of apoptotic cells in the infected slices while incubation time increased, ALA development causes severe destruction of the liver tissue, This is consistent with what was said (8) amoeba that induce the programmed death of hepatic cells and noted that it increased in number the progress of infected time.

In Table (1) Were observed levels liver enzymes increased directly proportional to the time of incubation , It was also noted high levels of these enzymes in the serum increased numbers damaged cells the process of Apoptosis ,Probably due to these enzymes mostly reside within the cells of the liver. But when the liver is injured for any reason, these enzymes are spilled into the blood stream . These enzymes are normally predominantly contained within liver cells and to a lesser degree in the muscle cells. If the liver is injured or damaged, the liver cells spill these enzymes into the blood, raising the aspartate aminotransferase (AST) and alanine aminotransferase (ALT) enzyme blood levels and signaling liver disease , While ALP is a substance found in the bile ducts of the liver , intestine and the bone. Damage or obstruction of the bile ducts may result in elevated levels of ALP. These tests can provide a host of information on a range of disease processes (10)

This is consistent with what he found (1) to note a high in the level of concentration of the enzyme ALP reached

90 % of the cases with a high level of enzyme GOT, GPT in the serum of patients infected with dysentery, This result matched the findings of the (22) as the very high levels of liver enzymes in the serum of patients infected with the parasite , as well as demonstrated (2) for an increase in the levels of liver enzymes in mice infected with parasite *Giardia lamblia* .

REFERENCES

- [1] Al-Kubaissi , Abdul – Wahab Badawi Hussien (2002) . Immunological and Epidemiological Study of Patients Infected with *Entamoeba histolytica* . Ph.D. thesis, College of Science , AL – Mustansiriyah University ., 125 pp.
- [2] Al - Ghanimi, Fatima Yusuf Ktan (2013). Study the opposite effect for some plant extracts on the parasite *Giardia lamblia* in mice infected laboratory. Master Thesis, College of Science, University of Al-Muthanna., 130 pp.
- [3] Andra, J.; Herbst, R. and Leippe, M. (2003). Amoebapore archaic effect for peptides of protozoan origin are discharged into phagosomes and kill bacteria by permeabilizing their membranes. *Developmental & Comparative Immunology* ., 27: 291–304.
- [4] Bernal - Redondo, R.M. (2001). Entamoebiosis-amibiasis intestinal. *Entamoeba histolytica, Entamoeba dispar*. *Boletín Médico del Hospital Infantil de México* ., 58: 217–219
- [5] Boettner, D.R. ; Huston, C.D. ; Linford, A.S. ; Buss, S.N., Houpt, E., Sherman, N.E. and Petri, W.A. (2008). *Entamoeba histolytica* phagocytosis of human erythrocytes involves PATMK, a member of the transmembrane kinase family. *PLoS Pathogens* ., 4: 122–133.
- [6] Bruchhaus, I., Roeder, T., Lotter, H., Schwerdtfeger, M. and Tannich, E. (2002). Differential gene expression in *Entamoeba histolytica* isolated from amoebic liver abscess. *Molecular Microbiology*. 44 :1063–1072.
- [7] Bruchhaus, I.; Loftus, B.J.; Hall, N. and Tannich, E. (2003). The intestinal protozoan parasite *Entamoeba histolytica* contains 20 cysteine protease genes, of which only a small subset is expressed during *in vitro* cultivation. *Eukaryotic Cell* ., 2: 501–509.
- [8] Carranza-Rosales, P.; Santiago-Mauricio, M.G.; Guzman-Delgado, N.; Vargas- Villarreal, J.; Lozano-Garza, G.; Viveros-Valdez, E. ; Ortiz-Lopez, R.; Moran-Martinez, J. and Gandolfi, A.J. (2012). Induction of virulence factors, apoptosis, and cytokines in precision-cut

- hamster liver slices infected with *Entamoebahistolytica* Experimental Parasitology, 132 : 424–433
- [9] Cenavece, (2010). Centro Nacional de Vigilancia Epidemiológica Control de Enfermedades, Secretaria de Salud, México. 1-6
- [10] Dufour, D. (2001). Evaluation of liver function and injury in clinical (Henry J editor). W. B. Saunders Company. 264 pp.
- [11] Eichinger, D.J. (2009). Amebiasis. In :Satoskar, A.R.; Simon, G.L.; Hotez, P. and Tsuji, M. (Eds.) Medical parasitology Landes Bioscience, USA., 171-182.
- [12] Fernandes, H.; Souza, C.R.; Swethadri, G.K. and Naik, C.R. (2009). Ameboma of the colon with amebic liver abscess mimicking metastatic colon cancer. Indian Journal of Pathology and Microbiology., 52 (2) : 228-230.
- [13] Gilchrist, C. and Petri, W.A. (1999). Virulence factors of *Entamoebahistolytica*. Current Opinion in Microbiology., 2: 433–437.
- [14] Haque, R.; Huston, C.D.; Hughes, Hout, E. and Petri, W.A. (2003). Current concepts: amebiasis. The New England Journal of Medicine., 348 : 1565–1573.
- [15] Huston, C.D., (2004). Parasite and hosts contributions to the pathogenesis of amebic colitis. Trends in Parasitology., 20, 23–26.
- [16] Lauwaet, T.; Oliveira, M.J.; Callewaert, B.; De Bruyne, G.; Mareel, M. and Leroy, A. (2004). Proteinase inhibitors TPCK and TLCK prevent *Entamoebahistolytica* disturbance of tight junctions and microvilli in enteric cell layer in vitro. International Journal of Parasitology., 34: 785–794.
- [17] Leippe, M.; Bruhn, H.; Hecht, O. and Grotzinger, J. (2005). Ancient weapons: the three dimensional structure of amoebapore A. Trends in Parasitology., 21: 5–7.
- [18] Moody-Haupt, S., Patterson, J.H., Mirelman, D. and McConville, M.J. (2000). The major surface antigens of *Entamoebahistolytica* trophozoites are GPI-anchored proteophosphoglycans. Journal of Molecular Biology., 297: 4-8
- [19] Mortimer, L. and Chadee, K. (2010). The immunopathogenesis of *Entamoebahistolytica*, Experimental Parasitology., 126 : 366–380.
- [20] Pelosof, L.C.; Davis, P.H.; Zhang, Z.; Zhang, X. and Stanley, S.L., (2006). Co-ordinate but disproportionate activation of apoptotic, regenerative and inflammatory pathways characterizes the liver response to acute amebic infection. Cellular Microbiology, 8: 508–522.
- [21] Pérez-Tamayo, R.; Montfort, I.; Olivos-García, A.; Ramos, E.; Nequiz, M. and Tello, E. (2006). Amibiasis hepática. Revista de Gastroenterología de México., 71: 47–72.
- [22] Pluta, H. and Pluta, J.N. (2008). Hepatic abscess: current approach to patients with pyogenic or amebic abscess. Gastroenterología y Hepatología., 15(5) : 343-346
- [23] Stanley, S.L. (2003). Amoebiasis. Lancet., 36: 481–489.
- [24] Tsutsumi, V., Mena-Lopez, R., Anaya-Velazquez, F. and Martínez-Palomo, A., (1984). Cellular bases of experimental amebic liver abscess formation. American Journal of Pathology., 117: 81–91.
- [25] Ventura-Juarez, J.; Campos-Rodríguez, R. and Tsutsumi, V. (2002). Early interactions of *Entamoebahistolytica* trophozoites with parenchymal and inflammatory cells in the hamster liver: an immunocytochemical study. Canadian Journal of Microbiology., 48: 123–131.
- [26] WHO (World Health Organization), 2009. State of the art of vaccine research and development. Initiative for Vaccine Research.
- [27] Zhang, X.; Zhang, Z.; Alexander, D.; Bracha, R.; Mirelman, D. and Stanley, S.L. (2004). Expression of amoebapores is required for full expression of *Entamoebahistolytica* virulence in amebic liver abscess but is not necessary for the induction of inflammation or tissue damage in amebic colitis. Infection and Immunity., 72: 678–683.